

The Use of Islanded Posterior Tibial Artery Perforator Flaps in Reconstruction of Pretibial Defects

SHERIF ELKASHTY, M.D.

The Department of Plastic and Reconstructive Surgery, Faculty of Medicine, Menoufia University, Egypt

ABSTRACT

Background: Soft tissue defects of lower limb particularly middle and distal thirds presents a challenge for reconstructive surgeons. Reconstructive options range from random local flaps ending up to free flaps and including perforator flaps. Posterior tibial artery perforator flaps present a very versatile reconstructive option in light of their advantages.

Purpose: The objective of this article is to evaluate the versatility of the islanded posterior tibial artery perforator flaps for reconstruction of middle and distal thirds of the leg.

Patients and Methods: Seventeen patients were included in this study in the period from February 2012 to September 2013. All patients were males, aged from 17 to 43 years. They had posttraumatic small to medium sized pretibial skin defects. Posterior tibial artery perforator flaps were elevated based on a nearby perforator and rotated to cover the defect with skin grafting of the flap donor site.

Results: The mean follow-up period was about 12 months. All flaps survived and provided stable coverage of the defects. One flap showed only marginal necrosis and managed conservatively. Two cases had partial losses of the skin grafts and managed conservatively. One patient had infection and managed conservatively. The flaps were aesthetically acceptable in males, with similar tissue characteristics to the reconstructed site.

Conclusion: The islanded posterior tibial artery perforator flap does seem to be a reliable versatile fasciocutaneous flap for coverage of small to medium sized pretibial soft tissue defects of the middle and lower thirds of the leg.

INTRODUCTION

Soft tissue defects of the lower extremity, especially distal third of the leg, presents a formidable challenge due to lack of reliable local flaps. Conventional reconstructive options include local random fasciocutaneous flaps, cross leg fasciocutaneous flaps, pedicled muscle or musclocutaneous flaps or free flaps. All these procedures have their limitations and associated morbidity at the donor site [1].

Reconstruction now addresses not only soft tissue coverage, but also takes into consideration

functional recovery, infection control, and cosmetic outcome. Evolution of perforator flaps started when survival of free flaps had already reached 98% [2].

Quest for refinement and reduction in donor site morbidity resulted in the development of the perforator flap. Perforator vessels are those where the source artery is deep and the branch that carries blood to the fasciocutaneous tissues passes through the overlying deep fascia [3].

There are three types of perforators; direct cutaneous perforators, septocutaneous perforators, and musclocutaneous perforators [4]. Musclocutaneous perforators are named according to the muscle perforated. Other perforators are named according to the name of the proximal source artery [5].

Venkataramakrishnan et al. [6], were the first to report posterior tibial artery perforator based flaps as local V-Y advancement flaps that totally eliminated the need for microsurgery. Hallock [7] reported a 180-degree rotation of a local posterior tibial artery perforator flap as early as 1993, which now would be called a propeller flap as another method allowing primary donor site closure [8].

One advantage of these perforator flaps is preservation of the posterior tibial source artery and the function of adjacent muscles. This can be used as a free flap [9,10], but is an even better option as a local flap for the distal leg that can completely avoid any microanastomoses [11,12,13]. Another advantage is that tissues similar to the recipient site in texture, thickness, color and hair bearing qualities can be reestablished.

The purpose of this study is to evaluate the versatility of the posterior tibial artery perforator flaps for reconstruction of small to medium sized posttraumatic pretibial defects of the middle and distal thirds of the leg.

PATIENTS AND METHODS

This study was done at The Department of Plastic and Reconstructive Surgery, Menoufia University Hospitals. It was done in the period from February 2012 to September 2013, with a follow-up period of an average of 12 months. The study included 17 patients, all were males, their age ranged from 17 to 43 years.

The defects were pretibial, small to medium in size, located about the middle and distal thirds of the leg, caused by motorcycle accidents, and associated with fracture of one or both bones of the leg. Ten patients had middle third pretibial defects and seven patients had distal third pretibial defects. Fractures were fixated with either external or internal fixation by orthopaedic surgeons and the patients were referred to our Plastic Department for coverage of soft tissue defects.

Surgical technique:

Preoperative detection and marking of perforators near the skin defect was done by an 8 MHz hand held Doppler. The flap was drawn adjacent to the defect, around the marked perforator as the pivot point of the flap, taking into account the size of the defect. The patient was placed supine, under spinal anesthesia, with flexion of the knee and external rotation of the leg.

A tourniquet was inflated without prior exsanguinations to facilitate identification of perforators as they remain filled with blood. All flaps were dissected under loupe magnification. An exploratory incision was done along the defect side of the flap, and dissection started in a subfascial plane, keeping in mind the expected site of the perforator(s). Once suitable perforator(s) was/were found, the dimensions of the flap were confirmed or changed to the extent as required.

Flap margins were then incised all around, so as to island the flap on the selected perforator.

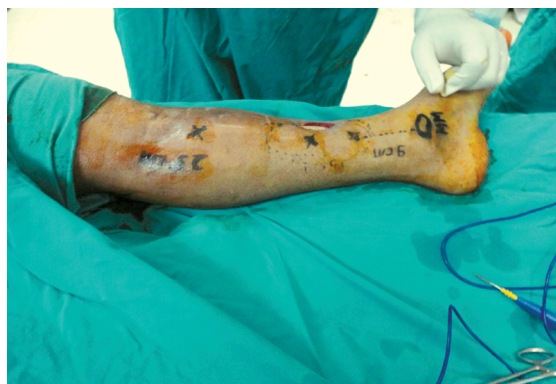

Fig. (1-A): Pretibial defect at distal third of leg, with marking of 2 perforators.

Adequate release of all fascial strands around the perforator(s), with dissection around the perforator(s) down into the intermuscular septa to gain additional length, was carried out to facilitate rotation of the flap without kinking of the perforator.

The tourniquet was deflated, hemostasis was done, and viability of the flap was evaluated. The flap was rotated or advanced into the defect and the position of the perforator was once checked again to avoid kinking of the perforator. The flap was inset and sutured into the defect and the flap donor site was skin grafted with split thickness grafts. The angle of Flap rotation ranged from about 30 to 120 degree as we could be able to find sizable perforator above or beside the defect respectively.

RESULTS

The whole seventeen flaps survived completely without flap loss. The average size of the flap was about 12x7cm. In one case, there was partial marginal flap necrosis at the edge farther from the perforator, managed conservatively with debridement and frequent dressing and healed spontaneously. The skin graft take was complete except in two cases, where there were patchy skin graft losses, managed conservatively and healed spontaneously.

Wound infection at the flap site had occurred in one patient, and managed by culture specific antibiotic and frequent dressing and healed uneventfully. None of the patients showed any sort of vascular impairment or sensibility changes due to dissection of flap perforators down to the posterior tibial axis.

The flaps provided stable coverage of the pretibial defects with adequate soft tissue contour and with similar characteristics to the lost skin in terms of texture, thickness, and color (Figs. 1,2,3).

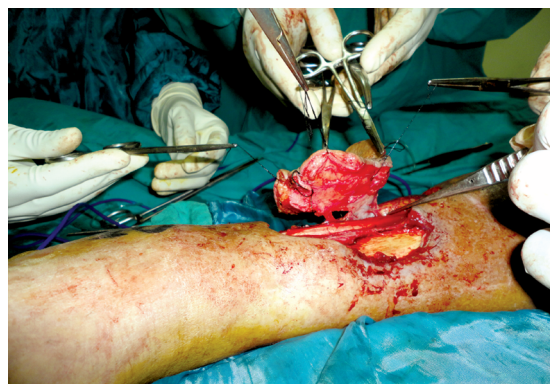


Fig. (1-B): Flap totally elevated and islanded on two septo-cutaneous perforators.

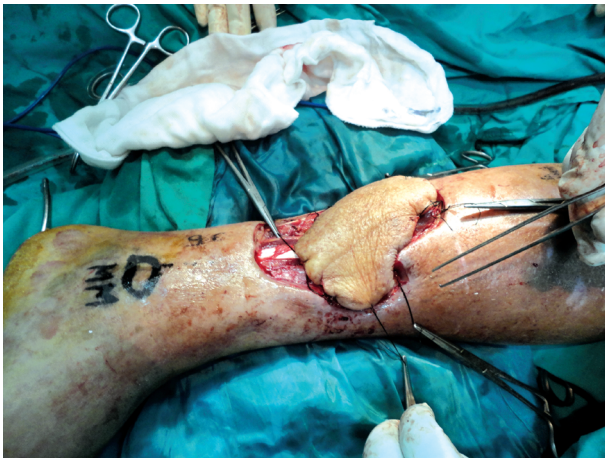

Fig. (1-C): The flap advanced into the defect.

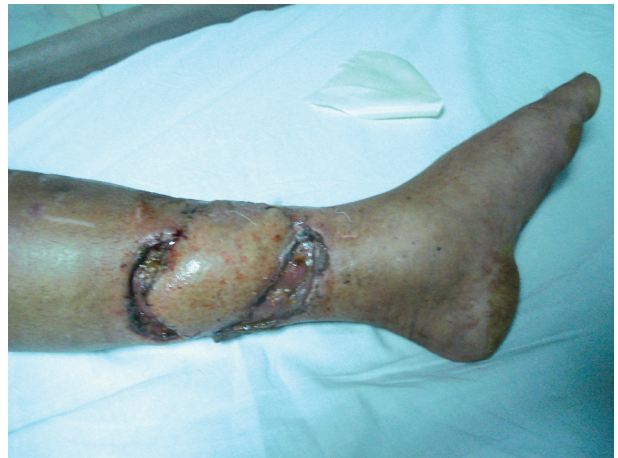

Fig. (1-D): Early postoperative result with skin grafting above and below the flap.

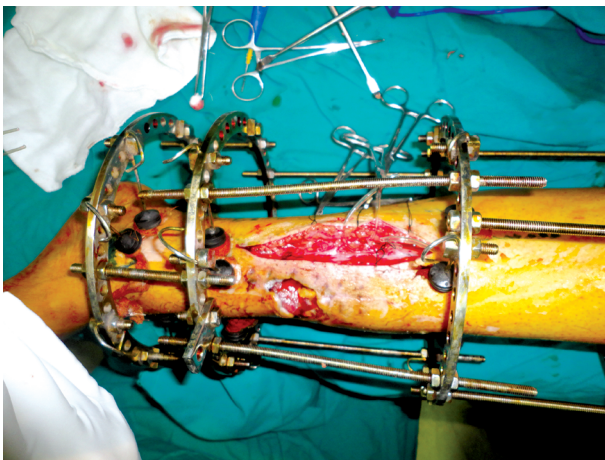


Fig. (2-A): Pretibial defect of the distal third of leg.

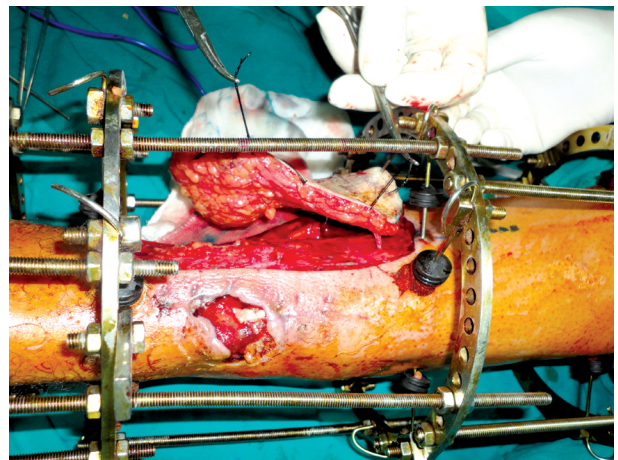


Fig. (2-B): The flap is totally elevated and islanded on a perforator above the pretibial defect.

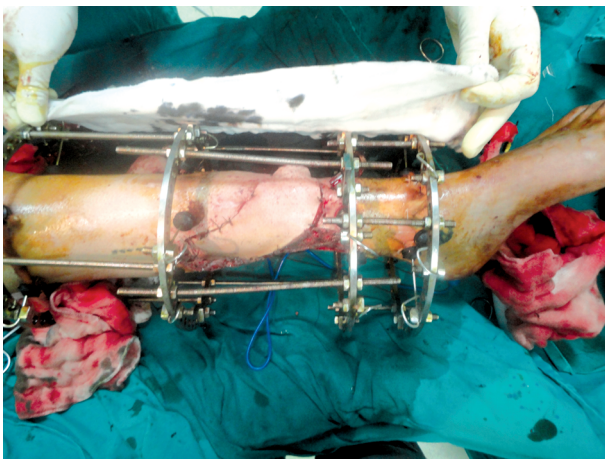


Fig. (2-C): The flap rotated about 30 degree into the pretibial defect.

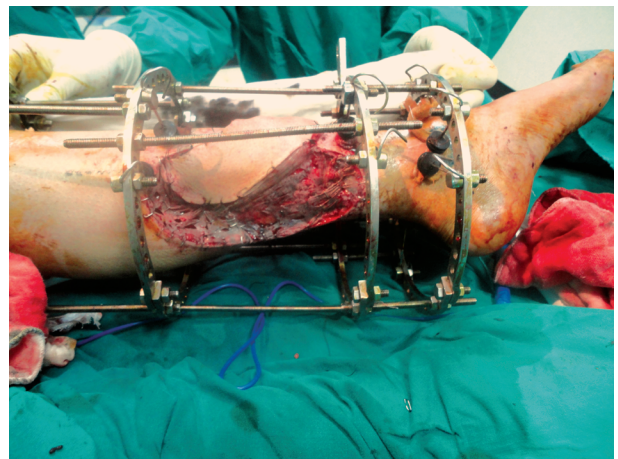


Fig. (2-D): Flap donor site skin grafted.

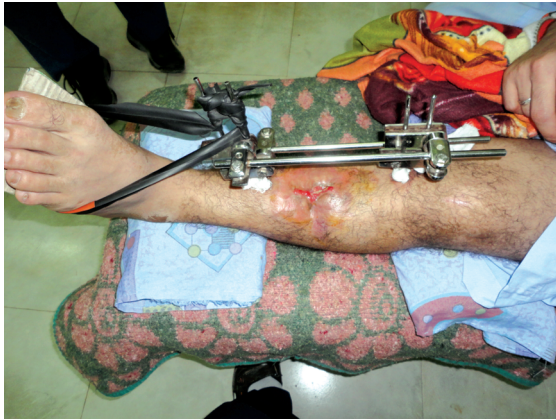

Fig. (3-A): Pretibial defect of the middle third of leg.

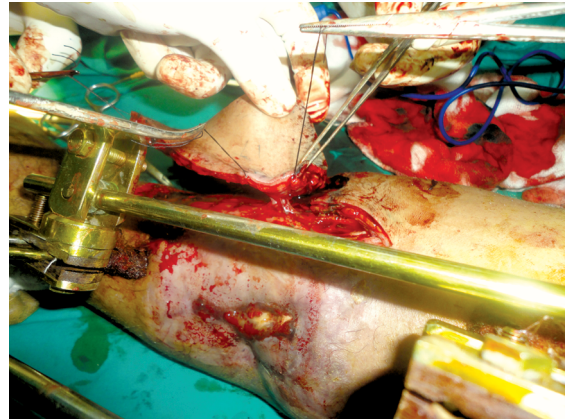


Fig. (3-B): Flap totally elevated and islanded on a perforator adjacent to the defect.

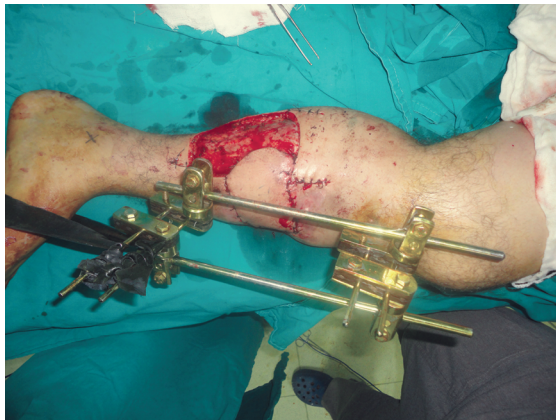

Fig. (3-C): The defect debrided, and the flap rotated about 120 degree into the defect.

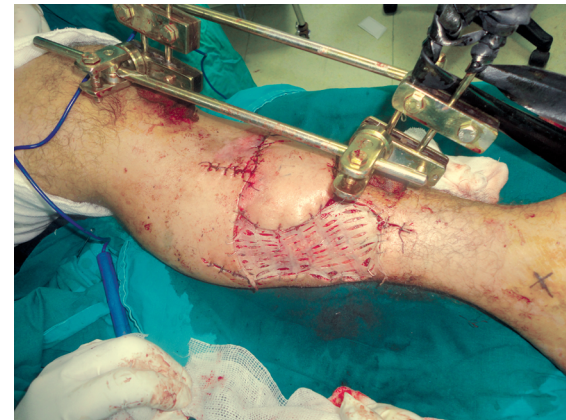


Fig. (3-D): Flap donor site skin grafted.

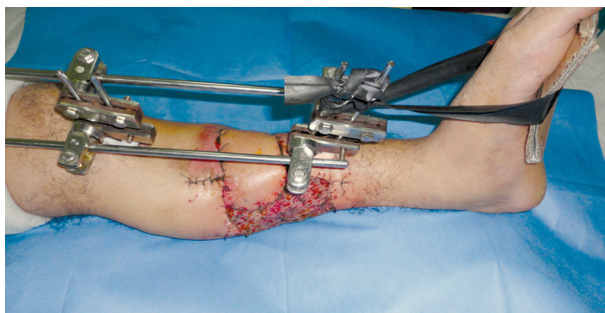

Fig. (3-E): Early postoperative result with adequate coverage of the defect.

DISCUSSION

Soft tissue defects of the lower extremity, especially distal third of the leg, presents a formidable challenge due to lack of reliable local flaps. Conventional reconstructive options include local random fasciocutaneous flaps, cross leg fasciocutaneous flaps, pedicled muscle or musculocutaneous flaps or free flaps. All these procedures have their limitations and associated morbidity at the donor site [1].

Reconstruction now addresses not only soft tissue coverage, but also takes into consideration functional recovery, infection control, and cosmetic outcome. Evolution of perforator flaps started when survival of free flaps had already reached 98% [2]. The reliability of flaps designed on the posterior tibial vessels was first demonstrated by Zhang et al. [14], and later by Masquelet and Romana [15] and Wu et al. [16].

Several clinical studies elucidated the specific vascular anatomy of the anteromedial aspect of the leg, indicating the upper and middle thirds as the most suitable regions which one should select to harvest local flaps based on perforator branches of the posterior tibial artery [17,18].

Robotti et al. [11], in their study had performed posterior tibial artery perforator flaps in 24 patients for reconstruction of soft tissue defects of the leg after tumor excision. They had a uniformly successful result except for a partial flap necrosis which had been managed conservatively and healed spontaneously, and one case of hematoma which

was drained without consequences on the final outcome. They stated the advantages of these perforator flaps as a quick and safe procedure, which provide good contour with excellent color, texture, and thickness match, with long term stability of the reconstruction at the expense of minimal donor site morbidity. These results are comparable with our results in terms of the minimal complication and the advantages of these perforator flaps.

Marcelo et al. [19], in their study performed 24 perforator flaps based on perforators from the three main vessels of the leg to cover skin defects of the middle and distal segments of the leg. In nine cases, the perforators originated from the fibular artery, in ten cases the perforators originated from the posterior tibial artery, and in five cases the perforators originated from the anterior tibial artery. The mean size of the flap was 12x5cm. The flaps were fully viable in 20 cases and partially viable in four cases. These four cases were either heavy smokers or old aged. In our study we had less number of partial flap necrosis, but we have a less number of patients in our study. We had no old age patients in our study, as our patients were young and middle age motorcycle rider males.

Erdmann et al. [20], reviewed their 66 cases (in 5 years) of islanded distally based posterior tibial perforator flaps and showed that the majority of the flaps (53) were used for posttraumatic soft tissue problems. The significant flap necrosis necessitating an alternative reconstruction, either by free flaps or another pedicle perforator flaps, occurred in 7% of cases. This was mostly encountered in patient with peripheral vascular disease or diabetes or in patients who had unrecognized degloving at the flap territory. Contrary to their result, we do not have significant flap necrosis in our study, but we have a smaller number (17) of patients in our study.

Keating et al. [21], used pedicled posterior tibial perforator flaps in the treatment of 26 open fractures of the distal third of the tibia (there were 8 Gustilo type II and 18 Gustilo type III fractures). Only two flaps underwent edge necrosis, which healed without further surgery. These results are in accordance with our results in terms of the minimal complication rate.

In conclusion, the results obtained in this study indicate that, the posterior tibial artery perforator based flaps add viable option to the armamentarium of the reconstructive surgeon. It is simple versatile

technique, less time consuming, with minimal donor site morbidity. It is ideal for reconstruction of small to medium size pretibial defects of the middle and distal thirds of the leg, with excellent color, texture, and thickness match. Their disadvantages are their limited role in reconstruction of large defects, variable location of the perforators, and inapplicability in cases with injury (either traumatic or surgical) to perforators or their skin territories.

REFERENCES

- 1- Hong J.P.: The use of supermicrosurgery in lower extremity reconstruction: The next step in evolution. *Plast. Reconstr. Surg.*, 123: 230, 2009.
- 2- Wei F.C. and Celik N.: Perforator flap entity. *Clin. Plast. Surg.*, 30: 325, 2003.
- 3- Geddes C.R., Morris S.F. and Neligan P.C.: Perforator flaps: Evolution, classification and application. *Ann. Plast. Surg.*, 50: 90, 2003.
- 4- Blondeel P.N., Vanlanduyt K., Hamdi M., et al.: Perforator flap terminology: update 2002. *Clin. Plast. Surg.*, 30: 343, 2003.
- 5- Kim J.T.: Nomenclature concept of flap. *Br. J. Plast. Surg.*, 58: 431, 2005.
- 6- Venkataramakrishnan V., Mohan D. and Villafane O.: Perforator based V-Y advancement flaps in the leg. *Br. J. Plast. Surg.*, 51: 431, 1998.
- 7- Haaock G.G.: Evaluation of fasciocutaneous perforators using color duplex imaging. *Plast. Reconstr. Surg.*, 94: 644, 1994.
- 8- Pignatti M., Ogawa R., Hallock G.G., et al.: The "Tokyo" consensus on perforator flaps. *Plast. Reconstr. Surg.*, 127: 716, 2011.
- 9- Koshima I. and Soeda S.: Free posterior tibial perforator-based flaps. *Ann. Plast. Surg.*, 26: 284, 1991.
- 10- Mardini S., Salgado C.J., Chen H.C., et al.: Posterior tibial artery flap in poliomyelitis patients with lower extremity paralysis. *Plast. Reconstr. Surg.*, 117: 640, 2006.
- 11- Robotti E., Carminati M., Banfiraro P.P., et al.: "On Demand" Posterior tibial artery flaps: A versatile surgical procedure for reconstruction of soft tissue defects of the leg after tumor excision. *Ann. Plast. Surg.*, 64: 202, 2010.
- 12- Schaverien M.V., Hamilton S.A., Fairbur N., et al.: Lower limb reconstruction using the islanded posterior tibial artery perforator flap. *Plast. Reconstr. Surg.*, 125: 1735, 2010.
- 13- Ozdemir R., Kocer U., Sahin B., et al.: Examination of the skin perforators of the posterior tibial artery on the leg and ankle region and their clinical use. *Plast. Reconstr. Surg.*, 117: 1619, 2006.
- 14- Zhang S., Li J., Song K., et al.: Clinical applications of the free posterior tibial flap. *Chin. Surg.*, 21: 743, 1983.
- 15- Masquelet A.C. and Romana M.C.: The medialis pedis flap: A new fasciocutaneous flap. *Plast. Reconstr. Surg.*, 85: 765, 1990.

- 16- Wu W.C., Chang Y.P., So Y.C., et al.: The anatomic basis and clinical application of flaps based on the posterior tibial vessels. *Br. J. Plast. Surg.*, 46: 470, 1993.
- 17- Shalaby H.A., Higazi M., Mandour S, et al.: Distally based medial island fasciocutaneous flap for repair of soft tissue defects of the lower leg. *Br.J. Plast. Surg.*, 44: 175, 1991.
- 18- Lees V. and Townend P.L.: Use of a pedicled fascial flap based on septocutaneous perforators of the posterior tibial artery for repair of distal lower limb defects. *Br. J. Plast. Surg.*, 45: 141, 1992.
- 19- Marcelo R.R., Neylor T.A., Wei T.H., et al.: Skin coverage of the middle-distal segment of the leg with a pedicled perforator flap. *J. Orthop. Trauma*, 24: 236, 2010.
- 20- Erdmann M., Court-Brown C.M. and Quaba A.A.: A five-year review of islanded distally based fasciocutaneous flaps on the lower limbs. *Br. J. Plast. Surg.*, 50: 421, 1997.
- 21- Keating J.F., Court-Brown C.M. and Quaba A.A.: Open tibial fractures. New Orleans, LA: Presented at the American Academy of Orthopaedic Surgeons, Annual Meeting, February 5, 1994.